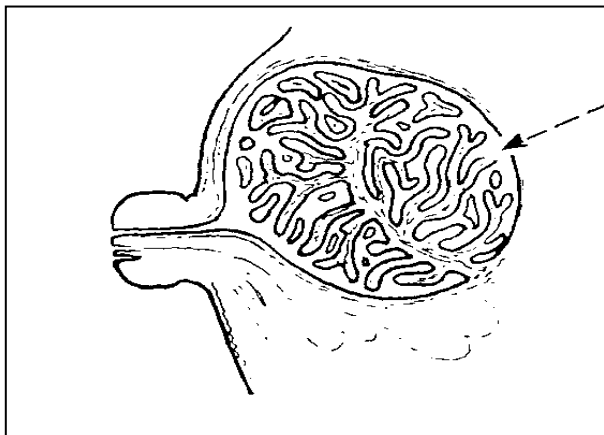


Breasts are defined medically as glandular tissue forming a radius of lobes containing alveoli, each lobe having a system of ducts for the passage of milk from the alveoli to the nipple. The central portion of the breast is filled with glandular tissue; the periphery is mostly of adipose tissue.

Over 50% of breast problems are lymphatic. Lymph stem cells originate in the bones which is why we find most (99%) breast cancer originates in the bone. From the stem cell come B Lymphocytes which control the sinuses in the breasts and T Lymphocytes which control the Alveoli in the breast.

Most medical books agree that "ductal carcinoma" is the most common form of breast cancer. We found the underlying cause (Ductal Deterioration Disease) and coupled it with Ductal Carcinoma plus RV Cell and call the remedy **Duct Cell Regeneration Complex**. The carcinoma is located in the duct or "in situ".



SUMMARY OF REMEDIES
 (with range of mega bottles needed)

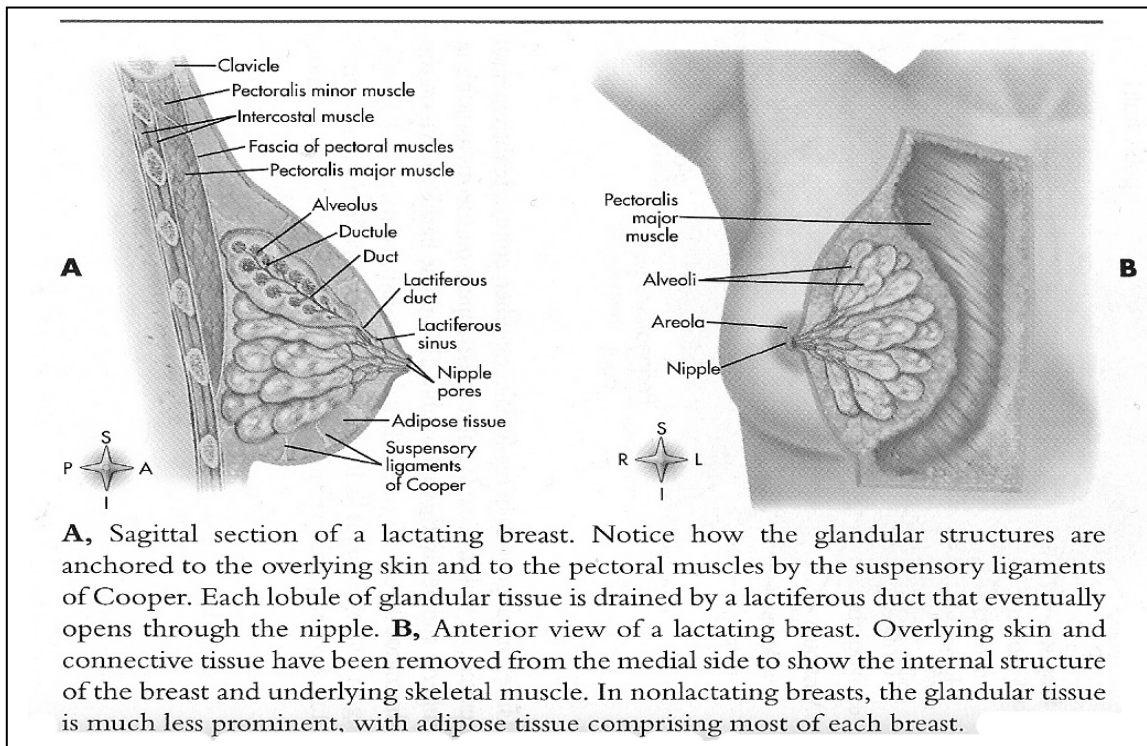
ALVEOLAR CELL CARCINOMA	4-6
ALVEOLAR CELL COMPLEX	4-6
ALVEOLAR CELL MALADY	4-5
CYSTOSARCOMA PHYILLODES	4-6
DUCT CELL REGENERATION COMPLEX	4-5
FIBROADENOMA	4-6
FOLLICULAR FALLACY COMPLEX	5-6
FOLLICULAR MALADY COMPLEX	5-6
INNER CAVITY	3-6
LOBULAR CARCINOMA	2-3
LYMPH NODE COMPLEX	3-5
LYMPHOMA (See Lymphoma protocol)	
MAST CELL COMPLEX	5-6
MEDULLARY CARCINOMA	4-6
MESENCHYME COMPLEX	3-6
METAPLASTIC DUCT DISEASE GROUP	4-5
MILK GLAND COMPLEX	4-5
MUCOUS WHIPPERZIPPER	4-5
MYTOSIS REGENERATE AND BOOST	
PAGETS	4-6
PLASMA TOXINS	3-5
TUBULAR CARCINOMA	4-6

When the term is used too loosely it will include the sinus portion of the breasts attached to the ducts. This lump is one of the most common and usually appears near the nipple. It is easy to discover in self examination.

This is often called a ductal carcinoma when technically and energy-wise it is a lacteal sinus papilloma. It also usually exudes a blood-like substance.

Other forms of "ductal carcinoma" can be in the milk ducts. For this we made **Milk Gland Complex**. Outside the ducts, but pressing on the ducts is called metaplastic ductal carcinoma. The symptoms are breast thickening, tenderness, discharge and change of appearance of the nipple. The breast skin changes include redness, scaling, puckering, dimpling, rash and breast pain. Essentially the ducts start to "fall apart". We use **Metaplastic Duct Disease Group**.

In 2010 we discovered a form of cancer that arises from the taking of chemotherapy **WHEN THE SUBJECT HAS A PREEXISTING CONDITION OF FOLLICULAR CELLS**. It therefore does NOT apply to every woman or every woman who had chemotherapy. The condition is described in a later section. We list here **Follicular Fallacy Complex** and **Follicular Malady Complex**. We most commonly see the need for one of these remedies after chemotherapy when the subject is trying to clean up "complications" and the health is going downhill when it is expected to go uphill.



In another section about Alveoli we detail the issues around **Alveolar Cell Carcinoma**. We described the common observation of alveolar problems in the lungs which are located behind the breasts. It is reasonable to suspect that alveolar problems in the lungs can give a warning about alveolar problems in the breasts.

Alveolar Cell Malady in this case may well support better lungs and better breasts.

Just as the lungs are structured as “lobes”, so are the breasts. Just as there is a Lobar Pneumonia in the lungs, there is a known **Lobular (also called Lobar) Carcinoma** in the breasts. The term refers to the lobes filling with some substance enough to cause the friction which leads to carcinoma. Although we have a remedy for **Lobar Carcinoma** (which needs a retrovirus), we suggest that the most likely material to fill the breasts is contained in the remedy for mucous.

Tubular Carcinoma is frankly poorly named and poorly described. It affects tubular shaped cells in the breasts (and more commonly can be seen in the tubules of the kidneys). Microscopes are needed for this identification.

Pagets is an inherited form of breast cancer that makes the nipple swollen, inflamed and red, with crusts on the surface. Often a fluid exudes from the nipple.

In advanced stages Pagets resembles leprosy of the breast, eating the nipple and inward.

Medullary Carcinoma has strong inflammation redness around the area. For unknown reasons, the redness often appears on the underside of the breast. Rare.

Fibroids of the breasts are from the same virus that forms fibroids of the uterus. The lumps are well circumscribed, rounded and elastic in consistency. They are often mobile, small and firm. Use **Fibroadenoma** with a retrovirus.

Sept.15, 2005 Notes for those who have had tubal ligations, which sometimes effect breasts.

Usually ovaries stop producing estrogen when the thymus stops producing an aminocyte that prepares estradiol in the kidneys for conversion into estrogen in the ovaries. The conversion process is driven by adrenal cortisol. (The same aminocyte is used by males in the kidneys for estradiol conversion to testosterone by the cells of Leydig (around the testicles)).

With a tubal ligation the estrogen produced by the ovaries cannot feed the uterus because the delivery route, the fallopian tubes are blocked. For some people the ovaries "leak" estrogen as if the ovaries were in the menstrual process. The backup of estrogen in the breasts is the sore breast syndrome felt by many women during menstruation.

The leaked estrogen is a toxin that makes breasts swell. The toxin is usually cleaned out of the breast by plasma, the liquid part of lymph. When an excess of plasma is needed for other issues as well as the normal monthly estrogen cleaning, a Plasma Abscess forms that often attracts a fungus, which is usually Cryptococcus Serotype C. We placed the 2 symbiotic remedies in one remedy called **PLASMA TOXINS**.

A **Cystosarcoma Phyllodes** is often described as a benign, sometimes malignant stromal (encapsulating tissue) breast tumor that grows rapidly. We include this remedy for those times. Studies show this will reoccur if not taken care of when it happens.

Mesenchyme is the meshwork of loosely organized embryonic connective tissue in the mesoderm from which are formed the connective tissues of the body and also the blood vessels and lymphatic vessels. The embryonic tissue stays as a foundation for other tissue and does not go away with adulthood. We have seen cases where the tissue of the breast formed a Mesenchymoma that was called breast cancer. In essence the issue is not a breast issue, but actually a tissue issue that happens to be on the breast. We put together a remedy for that causative disease, the lump and a retrovirus in a remedy called **Mesenchyme Regeneration Complex**.

Sinuses create mucin for the lubrication of the body, like friendly grease that decreases the friction of muscles and glands rubbing together. Since sinuses are controlled by B Lymphocytes made in the ileac crest of the hips, the mucin degrades to mucous when the infected bones decrease the quality of the mucin. The resulting mucous creates a diffuse Muroid Carcinoma throughout the breasts which clog the different flows of the breasts. There are a group of issues that go into the friction-based carcinoma. Thankfully the group of issues for this carcinoma with a retrovirus are so intertwined that we were able to put all the elements into a single remedy called **Mucous Whipperzipper**. The remedy cleans more than the breast.

In 2011 we found that the **Hilus Cell Complex** remedied a growing phenomena that had puzzled doctors for a long time. Lumps/tumors begin to grow in the ovarian area and were called ovarian tumors. The tumors “metasticized” to the abdomen, to the breasts and even to the adrenals. This is the description of a cell disease, not a metasticizing ovarian tumor. There are accompanying signs of virilization – unwanted facial hair and excess pubic hair. The disease has strong relationship to Phytanic Acid Storage Disease.

Evidence that the Mast Cell forms a non-hodgkin’s lymphoma that directly affects the breast has been mounting for years. We now include it as a possible complication.

A rare find was made with the discovery that the cells of the lining of the Endometrium (Basal lamnia - #2 in the drawing) or Epididymis are carried through the blood to nerves. The substance strangles nerves, causes genital problems and can cause debilitating back pains. There have even been cases where the nerves are so contracted that the leg has been drawn upwards, leaving the person limping or debilitated. We made **Membranous Contractus Complex**.

SUMMARY OF REMEDIES
(with range of mega bottles needed)

HILUS CELL COMPLEX	5-6
MAST CELL COMPLEX	5-6
MEMBRANOUS CONTRACTUS COMPLEX	5-6

